

The Unusual Case of A Sternoclavicular Joint Cyst In A 21 Months Old Child

Stefan Bittmann, Elisabeth Luchter, Gloria Villalon, Elena Moschüring-Alieva

Abstract

Sternoclavicular joint cysts are extremely rare in children. We report the 6th case of a ganglion of the sternoclavicular joint in a child, which was diagnosed by ultrasonography.

Keywords: Sternoclavicular Joint; Cyst; Synovial Cyst; Ganglion; Child

Introduction

Sternoclavicular joint cysts are extremely rare in childhood. Only 5 cases have been reported thus far in the medical literature [1]. We describe a case of a paraarticular cyst of the right sternoclavicular (SC) joint in a child.

Case Report

A child referred to our pediatric department with a 6 month history of a firm, painless swelling at the ventral aspect of the right sternoclavicular joint which enlarged slowly over time. At clinical examination, the size of the lesion was estimated to be approximately in 2 cm in diameter. A conventional radiograph (Figure 1) showed no obvious osseous or soft tissue abnormality. Ultrasound examination (Figure 2) revealed a para-articular cyst with a small stalk communicating with the right sternoclavicular joint. Due to the asymptomatic nature of the lesion, no surgical intervention was undertaken.

Discussion

Many different conditions may be associated with the sternoclavicular (SC) joint. Hyperostosis of the sternoclavicular joint, osteitis condensans, Friedrich's syndrome, Tietze's disease, subluxation of the SC joint, and ganglion cystic lesions. All of these conditions are rare in childhood. Ganglia are structures of cystic form surrounded by fibrous layer without a synovial structure and are full of mucinous fluid. They most commonly present as masses around hand that can induce compressive symptoms. They may be found near most major joints. Their etiology is unclear. On ultrasound they typically described as anechoic masses, and

Department of Pediatrics, Ped Mind Institute (PMI), Gronau, Germany

Corresponding Author: Stefan Bittmann, Head of the Department of Pediatrics and Ped Mind Institute (PMI) Pediatrician, Hindenburgring, Gronau, Germany.

Accepted Date: 22-04-2021

Published Date: 22-05-2021

Copyright © 2021 by Bittmann S. All rights reserved. This is an open access article distributed under the terms of the Creative Commons Attribution License, which permits unrestricted use, distribution, and reproduction in any medium, provided the original author and source are credited.

may have a communication with a joint or tendon tissue (see Figure 1). In adults, synovial cysts originating from the sternoclavicular joints were described with rheumatoid arthritis, spondyarthropathies, enthesitis and psoriatic arthritis [2,3,4-7]. Ganglion cysts that have their origin from the sternoclavicular joint have only been reported once in childhood. Haber et al described the first 5 cases of sternoclavicular joint cysts in children. In this study, only 1 patient was symptomatic. Biopsy was performed in 3 patients and the diagnosis of a ganglion cyst was confirmed

by histological analysis. No recurrence was found and present in this study. Haber recommended observation of asymptomatic cystic lesions that arise in the sternoclavicular joint. No extensive study concerning the treatment of ganglion cysts of the SC-joint has been reported in the medical literature so far. The most often described and published cases are single cases. Asymptomatic patients should be observed and symptomatic patients may be best treated with steroid injection or cyst excision.

Figure 1: No abnormality is discernable in a radiograph of the right SC joint with a lead marker taped to the superior aspect of the subcutaneous swelling.

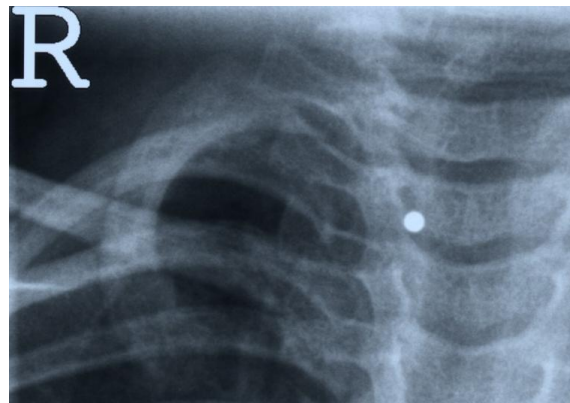
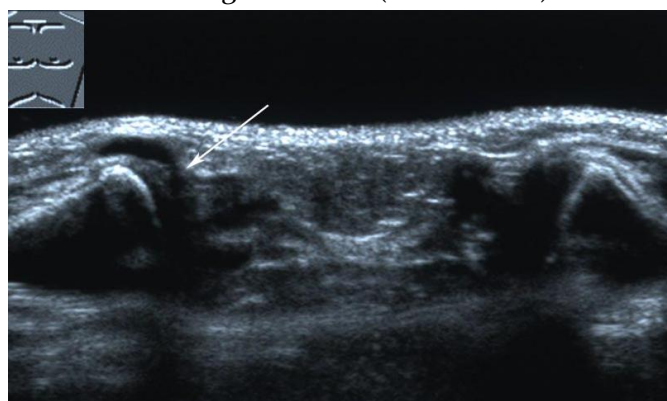


Figure 2: An axial ultrasound image of both sternoclavicular joints, using a broadband (frequency 8-14 MHz) linear array transducer and a standoff gel pad, shows an anechogenic cystic structure communicating via a stalk (white arrow) with the right SC joint.



References

1. Haber LH, Waanders NA, Thompson GH, Petersilge C, Ballock RT. Sternoclavicular joint ganglion cysts in young children. *J Pediatr Orthop* 22 (4): 544-7 (2002)

2. Andonopoulos AP, Meimaris N, Yiannopoulos G, Pastromas V, Dimopoulos P. Large synovial cysts originating from the sternoclavicular joints in a patient with rheumatoid arthritis. *Ann Rheum Dis* 62(11):1119-20 (2003)
3. Louvel JP, Duvey A, Da Silva F, Primard E, Mejjad O, Henry J, Le Loet X. Computed tomography of sternoclavicular joint lesions in spondylarthropathies. *Skeletal Radiol* 26(7):419-23 (1997)
4. Taccari E, Spadaro A, Riccieri V, Guerrisi R, Guerrisi V, Zoppini A. Sternoclavicular joint disease in psoriatic arthritis. *Ann Rheum Dis* 51(3):372-4 (1992)
5. Kim NG, Lim YS, Choi JH, Kim JS, Lee KS. Ganglion Cyst of the Sternoclavicular Joint in an Adult. *Arch Craniofac Surg*. 2014 Apr;15(1):40-42.
6. Negrete-Castañeda S, Bañuelos-Talavera LA, Grangeno-Aguirre J. Ganglión de la articulación esternoclavicular [Sternoclavicular joint ganglion]. *Acta Ortop Mex*. 2012 Nov-Dec;26(6):379-81. Spanish. PMID: 24712206.
7. Huang PY, Chang LS, Guo MM, Kuo HC. Successful treatment in a child with enthesitis-related arthritis involving the sternoclavicular joint: a case report. *BMC Pediatr*. 2019 Oct 23;19(1):373. doi: 10.1186/s12887-019-1770-6. PMID: 31647009; PMCID: PMC6806564.